

## ***Three dimensional comparison of maxillary sinus volume in patients with and without posterior crossbite Maxillary sinus volume***

***Atılım AKKURT<sup>1</sup>, Mehmet DOĞRU<sup>1</sup>, Seyit HEKİMOĞLU<sup>1</sup>, İrfan KARADEDE<sup>1</sup>***

*<sup>1</sup>Department of Orthodontics, Faculty of Dentistry, University of Dicle, 21280, Diyarbakir, Turkey*

### **Abstract**

**Objective:** *To compare the maxillary sinus (MS) volumes of the patients' with and without posterior crossbite (PCB).*

**Subjects and Methods:** *The CBCT scans of 2 groups were studied: (1) 50 patients (mean age: 14.39±1.32 years) without posterior crossbite (NCB); (2) 24 patients (mean age: 14.15±1.53 years) with PCB.*

*After the volume calculation with using Dolphin 11.0 (Dolphin Imaging, Chatsworth, Calif, USA) software, paired sample t test was used to compare the differences between the right and left maxillary sinus volume of each group. Independent sample t test was used to identify the left, right and mean maxillary sinus volume differences between groups.*

**Results:** *No significant differences were observed between right and left maxillary sinus volume for each group ( $p > .05$ ). Right, left and mean maxillary sinus volume calculated from PCB group was found significantly lower than those calculated from NCB group ( $p < .01$ ).*

**Conclusion:** *Right, left and mean MS volumes of PCB patients' were significantly lower than NCB individuals.*

**Keywords:** *CBCT, Maxillary Sinus Volume, Posterior Crossbite*

---

\* Corresponding author: E-mail: [aakkurt@dicle.edu.tr](mailto:aakkurt@dicle.edu.tr) , GSM: +90 505 238 0437

## Introduction

Paranasal sinuses are pneumatic and the anatomy of this structure varies from one individual to another.<sup>1</sup> Despite different hypotheses such as serving the resonance cavity for speech, dampening, warming during inspiration and cushioning for mastication, the functional importance of the paranasal sinuses has not yet been clearly understood.<sup>2</sup> However, some studies<sup>3</sup> claimed that MS plays an important role in the formation of facial contours.

The Maxillary sinus (MS) is the largest of the four paranasal sinuses.<sup>4</sup> The shape of this structure is pyramidal and the floor of this pyramid is comprised by the alveolar and palatine process of the maxilla.<sup>5</sup> MS has 2 rapid growth phases between the 0-3 and 7-12 years of ages but modest enlargement occurs until person's late teens.<sup>6</sup> However, Jun et al reported that the development of MS continued up until the third decade in males and second decade in female and thereafter its size decreased.<sup>3</sup>

Posterior crossbite (PCB) one of the most common malocclusion<sup>7</sup> is defined as lingually positioning of the maxillary posterior teeth relative to the mandibular teeth and often reflects a narrow maxillary dental arc.<sup>8</sup> It may arise from prolonged retention or premature loss of deciduous teeth, crowding, palatal cleft, genetic control and impaired nasal breathing caused by for example enlarged tonsils and adenoids.<sup>9-11</sup>

In the literature,<sup>12</sup> the relationship between MS volume and orthodontic malocclusions by using two dimensional (2D) imaging systems were reported. However, Ariji et al<sup>13</sup> concluded that 2D imaging systems were not suitable for MS volume calculation. In recent years Cone-Beam Computed Tomography (CBCT) systems has been widely used due to the advantages such as, creating three dimensional (3D) anatomically true images<sup>14</sup> and providing lower radiation dose<sup>15</sup> when compared with conventional tomography systems.

Previous studies evaluated the MS volume and volume changes related with different problems by using 3D imaging systems.<sup>1,3,16,17</sup> On the other hand the effects of PCB on craniofacial structures were evaluated and reported that this malocclusion may have long term effects on the growth and development of the teeth and jaws.<sup>18</sup> Since the growth of MS has a direct relationship with the palate and alveolar bone,<sup>17</sup> its' growth and volume may be affected by PCB. However to our knowledge, there are no published studies which evaluated the MS volume of PCB patients by using 3D imaging systems. Therefore, the purpose of this study was to test the null hypotheses that: (1) there are no significant differences between the right and left MS volumes of PCB and non-crossbite (NCB) patients and (2) there are no significant left, right and mean MS volume differences between PCB and NCB patients.

## Materials and Methods

The power of the sample size was calculated and it was determined that 10, 9 and 9 subjects would be needed to conduct this study with, 85.9%, 86.1% and 86.7% power ( $\alpha=.05$ ) for right, left and mean MS volume respectively.

The material of this study is consisted of 92 patients' CBCT scans selected from the archive of Oral and Maxillofacial Radiology and Orthodontic Department of Faculty of Dentistry, Dicle University. After a careful evaluation 18 PCB patients were excluded due to the MS pathology and a total of 74 patients' CBCT scans that fulfilled the inclusion criteria (Table 1) were used in the current study.

Table 1. Inclusion Criteria for Sample Selection

Non Crossbite Group	Posterior Crossbite Group
Skeletal Class I relationship without posterior cross bite	Skeletal Class I relationship with involving at least 3 posterior teeth in bilateral posterior cross bite at both sides
No history of trauma, previous orthodontic, prosthodontic treatment, or maxillofacial and plastic surgery	
All maxillary teeth present without any impaction except the third molars	
No signs or symptoms of maxillary sinus pathology (Maxillary Sinus Cist, Sinusitis, etc...)	

The CBCT scans were divided into two groups: Group 1 consisted of 50 patients' CBCT scans (22 girl, 23 boy; mean age: 14.39±1.32 years) without PCB as a control group (NCB); Group 2 consisted of 24 patients' CBCT scans (14 girl, 10 boy; mean age: 14.15±1.53 years) who had bilateral PCB (PCB). Cephalometric values are given in Table 2.

The CBCT scans of PCB group were provided for another research and the ethical approval had already been obtained from the Ethical Committee of the Dicle University (DUD-FEK 2009/21). Since the CBCT scans available in the archive due to the reasons such as temporomandibular joint assessment, detection of vertical root fracture and evaluation of mandibular impacted teeth were included in this study, another ethical approval was not needed for NCB group. No additional radiographies were taken specifically for cephalometric analysis or other diagnostic purposes.

All CBCT images were acquired with an iCAT 3D imaging device (Imaging Sciences International, Hatfield, Pa). The device was set for 5.0 mA and 120 kV. A 9.6-second scan with a single 360 degree rotation created images with a voxel size of 0.3 mm. As a routine image exposure protocol, the patients' heads were oriented by adjusting the Frankfort plane parallel to the horizontal plane, and the CBCT scans were taken while the patients bite into maximum intercuspation.

For the calculation of MS volumes, Digital Imaging and Communications in Medicine (DICOM) files obtained from the CBCT scans were exported to the Dolphin 11.0 (Dolphin Imaging, Chatsworth, Calif, USA) Imaging software. After carefully identification of the borders of MS in axial, sagittal and coronal views (Figure 1-3), all tomographies were carefully scanned slice by slice and the calculation of MS volumes were accomplished by adding the seeds to the unmarked areas by using the 3D module of the software.

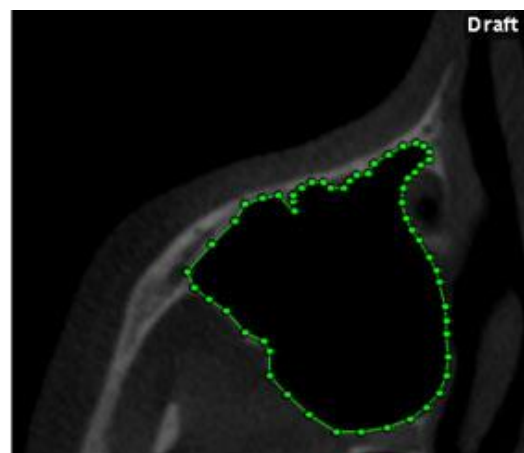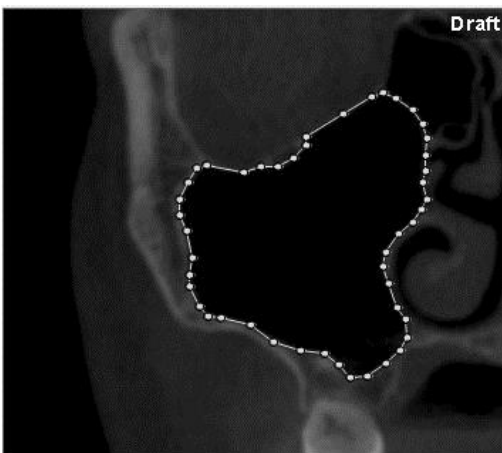


Figure.1 Maxillary sinus borders in coronal slice view. Figure.2 Maxillary sinus borders in axial slice view.

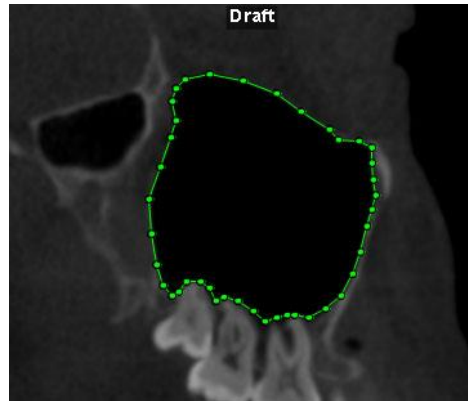


Figure.3 Maxillary sinus borders in sagittal slice view.

All measurements were made by the same author (A.A.) by using the same airway sensitivity parameter of software.

### Method Error

For method error evaluation, right and left MS volumes of randomly selected 15 patients from NCB and PCB groups were calculated after 4 weeks by the same examiner (A.A.). Paired sample *t* test and intra-class correlation coefficient were used to detect the differences between the first and second measurements with the level of significance set at  $p < 0.05$ .

### Statistical Analyses

Maxillary sinus volumes obtained from Dolphin Imaging software were analyzed with using Statistical Package for the Social Sciences (SPSS), version 16.0 (SPSS Inc, Chicago,III). Paired samples *t* test was used to compare the differences between the right and left maxillary sinus volumes of NCB and PCB groups. Independent samples *t* test was used to compare the right, left and mean MS volume between NCB and PCB groups. Probability values less than .05 were accepted as significant.

### Result

The differences between repeated measurements to detect the method error showed no significant differences for right and left sides of the PCB ( $p = .907$ ,  $p = .392$ ) and NCB ( $p = .224$ ,  $p = .592$ ) groups respectively. Intra-class correlation coefficient showed a good reproducibility with a minimum value of .835.

Descriptive statistics and paired sample *t* test results of groups are given in Table 2. The results showed no significant differences between the right ( $14653.78 \pm 3087.89 \text{ mm}^3$ ) and left ( $14886.18 \pm 2840.02 \text{ mm}^3$ ) MS volumes of NCB group ( $p > .05$ ). No significant differences were found from the comparison of right ( $12420.33 \pm 2902.35 \text{ mm}^3$ ) and left ( $12619.25 \pm 3072.49 \text{ mm}^3$ ) MS volumes of PCB group ( $p > .05$ ).

*Table 2. Descriptive Statistics and Right and Left Maxillary Sinus Volume Comparisons of Each Group.*

Group	SNA	ANB		Mean (mm <sup>3</sup> )	Sd	Min	Max	p value	
NCB (n=24)	77.63±2.1	2.02±1.02	Right Volume	14653.78	3087.89	11220	27012	p=.364	N.S.
			Left Volume	14886.18	2840.02	11666	24920		
			Mean Volume	14769.98	2953.83	11220	27012		
PCB (n=50)	77.26±2.9	2.42±1	Right Volume	12420.33	2902.35	8057	18570	p=.601	N.S.
			Left Volume	12619.25	3072.49	6762	17388		
			Mean Volume	12528.91	2932.39	6762	18570		

N.S: Not Significant

Independent sample t test results are given in Table 3. Side to side comparisons of both groups showed significant differences. Right MS volume of NCB group was found greater than that calculated from the right volume of PCB group (p= .004). Left MS volume of NCB group was also found significantly greater than that calculated from left volume of PCB group (p= .003). Similarly, mean MS volume of NCB group (14769.98 ± 2953.83 mm<sup>3</sup>) was found greater than mean MS volume (12528.91 ± 2932.39 mm<sup>3</sup>) that calculated from PCB group (p=0.002). According to this result, null hypothesis was rejected.

*Table 3. Independent Sample t Test results.*

	Mean Difference	Std. Error Differences	95% Confidence Interval of the Differences		p	
			Lower	Upper		
NCB (RV) / PCB (RV)	2233.18	752.39	733.3	3733.05	.004	**
NCB (LV) / PCB (LV)	2266.67	724.19	764.11	3769.23	.003	**
NCB (MV) / PCB (MV)	2249.92	703.49	847.52	3652.32	.002	**

(RV): Right Volume, (LV): Left Volume, (MV): Mean Maxillary Sinus Volume, \*\*\*: p<0.01

## Discussion

PCB is a common malocclusion and the etiology of this problem is multifactorial.<sup>9,18</sup> Different studies<sup>7,18</sup> were evaluated the effects of PCB on dentofacial structures. But to our knowledge, no published studies found which evaluated the MS volumes of PCB patients. Thus, the aim of this study is to evaluate the MS volume of PCB patients and compare them with NCB individuals by using CBCT.

In literature, the effects of gender on MS volume were evaluated. While some of these studies,<sup>1,17,19</sup> reported no significant differences, the others<sup>20</sup> concluded that males had larger MS volumes than females. On the other hand, Park et al<sup>16</sup> and Kim et al<sup>21</sup> did not consider gender discrimination in the evaluation of MS volume. In the present study, 18 of 42 (42%) PCB patients who had maxillary sinus pathology were excluded from the study. Thus, gender discrimination was not evaluated due to the small sample size. This may be considered as a weakness of the current study.

The result of this study revealed no significant MS volume differences between right and left side for NCB ( $p > .05$ ) and PCB ( $p > .05$ ) groups. Previous studies were evaluated the side differences about MS volume and did not find any significant differences.<sup>1,16,17,19,20</sup> Our finding is compatible with the results of previous studies.

In literature the MS volume has been reported to range between 8.6 cm<sup>3</sup> to 24.9 cm<sup>3</sup> from different studies.<sup>4,22</sup> In the current study, the mean MS volume obtained from NCB is 14769.9 ± 2953 mm<sup>3</sup>. Similar MS volumes were reported from previous studies.<sup>16,3,13</sup> On the other hand, some studies<sup>1,17,23</sup> reported greater MS volumes than the volumes obtained by present study. Emirzeoglu et al<sup>1</sup> and Cho et al<sup>17</sup> were calculated the MS volume of patients between 18 and 70 years old without any dental description. During adulthood, the shape and size of MS change especially due to loss of teeth.<sup>24</sup> Taguchi et al<sup>25</sup> concluded that loss of posterior teeth may be associated with a decrease in alveolar bone height and MS volume may increase with alveolar bone loss.<sup>17</sup> Kirmier et al<sup>23</sup> calculated the MS volume of the patients between the ages of 20-30 years old. Although it has been reported<sup>1,16</sup> that MS pneumatization is completed between 12 and 14 years of age, Jun et al<sup>3</sup> reported that the development of MS continued up until the third decade in males and the second decade in females. Therefore greater volumes obtained from the studies by Emirzeoglu et al,<sup>1</sup> Cho et al<sup>17</sup> and Kirmier et al<sup>23</sup> may be attributed to the wide age ranges.

Results of the current study indicated that mean, left and right MS volume obtained from PCB group is significantly lower than those obtained from NCB group ( $p < .01$ ). To date, there are no published studies which evaluated the MS volume of PCB patients thus we couldn't compare our findings with another study. However, according to the results of this study MS volume is affected by PCB.

Although not clearly understood, mechanisms such as nasal airflow and facial structures are related with the growth of the paranasal sinuses.<sup>26</sup> Similarly, nasal airflow restrictions<sup>11</sup> and adenoid<sup>9,10</sup> problems which result in mouth breathing<sup>27</sup> and facial muscle balance changes<sup>26,28</sup> due to the tongue position also affect the formation of PCB. The effects of these factors on skeletal growth and development such as narrow plate may be explained by functional matrix theory (FMT)<sup>29</sup>. According to Kikuchi,<sup>30</sup> the FMT by Moss claims that body functions such as breathing and deglutition affect the growth of the cartilage and bones as secondary changes. Since MS is located in the body of maxilla,<sup>2</sup> reduced MS volume of PCB patients as found in the current study may be attributed to the similar factors related with the formation of PCB and the growth of MS via FMT. On the other hand; although the effects of these factors<sup>26-29</sup> in the formation of PCB are well documented, the effects of these factors on MS development are controversial. Guimarães et al<sup>31</sup> evaluated nasal breath and its relation with maxillary sinus development with using CBCT images of seven patients and reported that posterior nasal air flow did not any crucial role in the MS development. Although a recent study<sup>32</sup> reported that increasing adenoid tissue volume did not significantly affect the development of paranasal sinuses, some studies<sup>33</sup> reported that adenoid tissue may impair the development of them. However, these otolaryngologic studies were not evaluated the MS volume of PCB patients.

The long term effects of PCB on MS volume may be clearly detected on longitudinal records. However because of the ethical concerns of CBCT imaging, current study was designed as a retrospective study and this may be considered as a limitation. Thus, large sampled longitudinal studies are needed to evaluate the developmental differences and volumetric changes in MS volume of PCB patients and to clarify whether it is an etiologic factor or a result of PCB.

## Conclusion

Within the limitations, the results of this study indicate that

There are no statistically significant side differences between right and left MS volumes of NCB and PCB groups.

Left, right and mean MS volume of PCB patients' were significantly lower than that of NCB individuals.

## References

1. Emirzeoglu M, Sahin B, Bilgic S, Celebi M, Uzun A. (2007). Volumetric evaluation of the paranasal sinuses in normal subjects using computer tomography images: a stereological study. *Auris Nasus Larynx*. 34:191-5.
2. Anagnostopoulou S, Venieratos D, Spyropoulos N. (1991). Classification of human maxillary sinuses according to their geometric features. *Anat Anz*. 173:121-30.
3. Jun BC, Song SW, Park CS, Lee DH, Cho KJ, Cho JH. (2005). The analysis of maxillary sinus aeration according to aging process; volume assessment by 3-dimensional reconstruction by high-resolutonal CT scanning. *Otolaryngol Head Neck Surg*. 132:429-34.
4. Sanchez Fernandez JM, Anta Escuredo JA, Sanchez Del Rey A, Montoya FS. Morphometric study of the paranasal sinuses in normal and pathological conditions. (2000) *Acta Otolaryngol*. 120:273-8.
5. Lund VJ. (1997). Anatomy of the nose and paranasal sinuses. In: Kerr AG, ed. *Scott Brown's Otolaryngology*. 6th ed. 1/5/1-29.
6. Graney DO, Rice DH. Anatomy. In: Cummings CW, Fredrickson JM, Harker LA, Krause CJ, Schuller DE. (1993) *Otolaryngology: head and neck surgery*, 2nd ed. St. Louis: Mosby Year Book. 901-6.
7. Egermark-Eriksson I, Carlsson GE, Magnusson T, Thilander B. (1990) A longitudinal study on malocclusion in relation to signs and symptoms of cranio-mandibular disorders in children and adolescents. *Eur J Orthod*. 12:399-407.
8. Isaacson JD, Ledley RS. Tooth Statics. (1964) *J Am Dent Assoc*. 69: 805-807.
9. Linder-Aronson S. (1970). Adenoids. Their effects on mode of breathing and nasal airflow and their relationships to characteristics of the facial skeleton and the dentition. *Acta Otolaryngol Suppl*. 265:1-132.
10. Peltomaki T. (2007). The effect of mode of breathing on craniofacial growth: revisited. *Eur J Orthod*. 29: 426-429.
11. Bresolin D, Shapiro GG, Shapiro PA, Dassel SW, Furukawa CT, Pierson WE, Chapko M, Bierman CW. (1984) Facial characteristics of children who breath through the mouth. *Pediatrics*. 73:622-625.
12. Oktay H. The study of the maxillary sinus areas in different orthodontic malocclusions. (1992) *Am J Orthod Dentofacial Orthop*. 102:143-5.
13. Ariji Y, Kuroki T, Moriguchi S, Ariji E, Kanda S. (1994) Age changes in the volume of the human maxillary sinus: a study using computed tomography. *Dentomaxillofac Radiol*. 23: 163-68.
14. Schlueter BA. (2007) *Cone Beam Computed Tomography Threedimensional Reconstruction for Evaluation of the Mandibular Condyle* [thesis]. St Louis, Mo: Saint Louis University.
15. Ludlow JB, Ivanovic M. (2008) Comparative dosimetry of dental CBCT devices and 64-slice CT for oral and maxillofacial radiology. *Oral Surg Oral Med Oral Pathol Oral Radiol Endod*. 106:106-14.
16. Park IH, Song JS, Choi H, Kim TH, Hoon S, Lee SH, Lee HM. (2010) Volumetric study in the development of paranasal sinuses by CT imaging in Asian: a pilot study. *Int J Pediatr Otorhinolaryngol*. 74:1347-50.
17. Cho SH, Kim TH, Kim KR, Lee JM, Lee DK, Kim JH, Im JJ, Park CJ, Hwang KG. (2010) Factors for maxillary sinus volume and craniofacial anatomical features in adults with chronic rhinosinusitis. *Arch Otolaryngol Head Neck Surg*. 136:610-5.
18. Kutin G, Hawes R. (1969) Posterior crossbites in the deciduous and mixed dentitions. *Am J Orthod*. 56:491-504.

19. Bargbrouth G, Prior JO, Lepori D, Duvoisin B, Schnyder P, Gudinchet F. (2002) Paranasal sinuses in children: size evaluation of maxillary, sphenoid and frontal sinuses by magnetic resonance imaging and proposal of volume index percentile curves. *Eur Radiol.* 12:1451–8.
20. Sahlstrand-Johnson P, Jannert M, Strömbeck A, Abul-Kasim K. (2011) Computed tomography measurements of different dimensions of maxillary and frontal sinuses. *BMC Med Imaging.* 5;1-8.
21. Kim HY, Kim MB, Dhong HJ, Jung YG, Min JY, Chung SK, Lee HJ, Chung SC, Ryu NG. (2008) Changes of maxillary sinus volume and bony thickness of the paranasal sinuses in longstanding pediatric chronic rhinosinusitis. *Int J Pediatr Otorhinolaryngol.* 72:103-8.
22. Kawarai Y, Fukushima K, Ogawa T, Nishizaki K, Gunduz M, Fujimoto M, Masuda Y. (1999) Volume quantification of healthy paranasal cavity by three-dimensional CT imaging. *Acta Otolaryngol Suppl.* 540:45-9.
23. Kirmeier R, Arnetzl C, Robl T, Payer M, Lorenzoni M, Jakse N. (2011) Reproducibility of volumetric measurements on maxillary sinuses. *Int J Oral Maxillofac Surg.* 40:195-9.
24. Teke HY, Duran S, Canturk N, Canturk G. (2007) Determination of gender by measuring the size of the maxillary sinuses in computerized tomography scans. *Surg Radiol Anat.* 29:9-13.
25. A Taguchi, Y Suei, M Ohtsuka, K Otani, K Tanimoto, L G Hollender. (1999) Relationship between bone mineral density and tooth loss in elderly Japanese women. *Dentomaxillofacial Radiol.* 28:219-223.
26. Kossowska EC, Gasik C. (1976) Results of surgical treatment of choanal atresia. *Rhinology.* 17:155-60.
27. Constantine J, George P, Ekonomides J, Dratsa J. (1994) The effect of hypertrophic adenoids and tonsils on the development of posterior cross bite and oral habits. *J Clinic Pediat Dent.* 18: 197–201.
28. Solow B, Siersbaek-Nielsen S, Greve E. (1984) Airway adequacy, head posture, and craniofacial morphology. *Am J Orthod* 86:214-23.
29. Moss ML. (1962) The functional matrix: functional cranial components. In: Kraus B, Riedel R, editors. *Vistas in orthodontics.* Philadelphia: Lea and Febiger. 85-90.
30. Kikuchi M. (2005) Orthodontic treatment in children to prevent sleep-disordered breathing in adulthood. *Sleep Breath.* 9:146-58.
31. Guimarães RE, Dos Anjos GC, Becker CG, Becker HM, Crosara PF, Galvão CP. (2007) Absence of nasal air flow and maxillary sinus development. *Braz J Otorhinolaryngol.* 73:161-4.
32. Apuhan T, Yıldırım YS, Öztaşlan H. (2011) The developmental relation between adenoid tissue and paranasal sinus volumes in 3-dimensional computed tomography assessment. *Otolaryngol Head Neck Surg.* 144:964-71.
33. Lusk RP, Stankiewicz JA. (1997) Pediatric rhinosinusitis. *Otolaryngol Head Neck Surg.* 117:53-57.